
Microsurgical Denervation of the Spermatic Cord for Chronic Orchialgia: Long-Term Results From a Single Center

Kurt H. Strom and Laurence A. Levine*,†

From the Department of Urology, Rush University Medical Center, Chicago, Illinois

Purpose: We assessed the long-term efficacy, complications and patient perceptions of microsurgical denervation of the spermatic cord in the treatment of chronic orchialgia.

Materials and Methods: Microsurgical denervation of the spermatic cord was performed on 95 testicular units in 79 men (mean age 40.3 years, mean duration of pain 62 months, 16 bilateral) for chronic orchialgia. Conservative management failed in all, and patients were evaluated with an extensive medical history and physical examination. To be a candidate for microsurgical denervation of the spermatic cord each man would have responded either completely or partially to spermatic cord block (greater than 50% decrease in pain) and had no identifiable reversible etiology. Postoperative pain rating scales (0 to 10) were used to determine efficacy.

Results: Mean followup was 20.3 months (range 1 to 102 months) and complete, durable relief was noted in 67 (71%) testicular units, partial relief in 17 (17%), and unchanged in 11 (12%). No patients reported worse pain. Complications included testicular atrophy without hypogonadism in 2 patients, superficial wound infection in 2, hydrocele in 2 and an incisional hematoma in 1.

Conclusions: Microsurgical denervation of the spermatic cord is a minimally invasive, effective and durable management option for treatment of chronic orchialgia refractory to medical management, preserving the physiological function and psychological role of the testes.

Key Words: testis, pain, spermatic cord, denervation

Chronic orchialgia significantly interferes with daily activities and is often a challenging management dilemma for urologists. It is defined as intermittent or constant, unilateral or bilateral testicular pain lasting for more than 3 months.¹ Nonsurgical treatments include antibiotics, analgesics, anti-inflammatory agents, antidepressants, anticonvulsants, regional and local nerve blocks, physical therapy, biofeedback, acupuncture and psychotherapy. Before presenting to a urologist, many patients have the condition for years and have been evaluated by multiple health care providers.

Plasticity of the peripheral and central nervous systems is believed to lead to chronic orchialgia resulting from chronically up-regulated peripheral and central pain pathways. This allows neurons in the PNS and CNS the capacity to change their function, gene expression, chemical and receptor profile, and/or structure resulting in chronic orchialgia.² Other chronic urological pain conditions including interstitial cystitis/painful bladder syndrome are thought to develop by similar mechanisms.³ With our current understanding of chronic pain the mechanism by which MDSC is postulated to alleviate orchialgia is to ablate the afferent nerve pathways contained in or on the internal spermatic veins, cremasteric musculature, and perivascular and spermatic cord fascia.

Management of chronic orchialgia should always proceed conservatively with medical therapy. When the aforementioned less aggressive modalities fail, patients are often willing to undergo surgery, even orchiectomy, for relief. Various options exist in addition to orchiectomy including epididymectomy, vasovasostomy and MDSC. We report our long-term results from June 1991 to August 2007 including efficacy, complications and patient perceptions. We also review the published reports on MDSC to treat chronic orchialgia (table 1).

MATERIALS AND METHODS

Patient Selection

Between June 1991 and August 2007, 79 men with 95 testicular units (16 bilateral) with chronic orchialgia underwent MDSC. Mean patient age was 40.3 years (range 17 to 65) (table 2). This retrospective analysis includes the experience of 27 men previously reported on in 2 published series.^{4,5} An additional 68 testicular units (72%) were treated between September 1999 and August 2007. Long-term followup was conducted by chart review, telephone interview and mailed investigator generated nonvalidated questionnaire.

The preoperative duration of orchialgia ranged from 5 to 252 months (mean 62) and followup was from 1 to 102 months (mean 20.3). Etiology and previous treatment were recorded. Conservative treatment had failed in all men, and the men were evaluated with a detailed medical history and focused physical examination. The medical history should

Submitted for publication January 3, 2008.

* Correspondence: 1725 W. Harrison Ave., Suite 352, Chicago, Illinois (telephone: 312-563-5000; e-mail: drlevine@hotmail.com).

† Financial interest and/or other relationship with Pfizer Inc, Auxilium Pharmaceuticals Inc, Bayer Pharmaceutical/GlaxoSmith-Kline, Lilly ICOS, American Medical Systems and Schering Inc.

TABLE 1. *Surgical treatment of orchialgia in the literature*

References	No. Units	Mos Followup	No. Success (%)		
			Complete	Partial	No Relief
Microsurgical denervation:					
Devine and Schellhammer ⁶	2	Not available	2 (100)	0	0
Choa and Swami ¹⁵	4	18.5	4 (100)	0	0
Levine et al ⁴	8	16.6	7 (88)	1 (12)	0
Ahmed et al ^{16,*}	17	Not available	13 (76)	4 (24)	0
Levine and Matkov ⁵	27	20	25 (76)	3 (9)	5 (15)
Heidenreich et al ¹⁷	35	31.5	34 (96)	1 (4)	0
Present series	95	20.3	67 (71)	17 (17)	11 (12)
Laparoscopic denervation:					
Cadeddu et al ^{18,†}	9	25.1	Not available	7 (78)	2 (28)
Vasectomy reversal:					
Shapiro and Silber ^{10,*}	6	Not available	6 (100)	0	0
Myers et al ^{11,*‡}	32	29	27 (84)	Not available	5 (16)
Nangia et al ^{12,*‡}	13	18	9 (69)	4 (31)	0
Epididymectomy:					
Davis et al ^{1,‡}	10	Not available	1 (10)	9 (90)	Not available
West et al ^{19,*‡}	16	66	Not available	14 (88)	Not available
Resection of genitofemoral nerve:					
Ducic and Dellon ²⁰	4	6	4 (100)	0	0
Orchiectomy:					
Davis et al ^{1,‡}					
Inguinal orchiectomy	15	Not available	11 (73)	4 (27)	0
Scrotal orchiectomy	9	Not available	5 (55)	3 (33)	1 (22)
Yamamoto et al ⁹ (inguinal)	4	Not available	3 (75)	1 (25)	0

* Post-vasectomy pain syndrome series.
 † Complete responders not characterized.
 ‡ Testicular units not available.

focus on previous genital infection, surgery on the spine, scrotal contents, inguinal or pelvic areas, local trauma, other chronic pain conditions, analgesic use and psychiatric disorders. Eliciting whether secondary gain issues are present is difficult. If these issues are suspected and the diagnostic process fails to find a cause, mental health referral is in order before surgery is offered. Detailed physical examination should be performed to identify the precise location of the pain (ie testicle, cord structures including vas deferens, epididymis). Urinalysis and semen culture when indicated are also recommended. Duplex scrotal ultrasound was performed at least once on all patients to exclude structural abnormality including tumor, torsion, varicocele, hydrocele, spermatocele, inguinal hernia and epididymo-orchitis. Computerized tomography or MRI of the spine was performed when a history of back pain or trauma was reported. When no reversible cause of the pain was identified, spermatic cord block was performed at the pubic tubercle area with 20 cc

0.5% bupivacaine. MDSC was offered only when complete or partial (50% reduction) temporary relief of pain was reported. All patients understood that the risks of the procedure included failure to alleviate the pain, infection, bleeding, loss of the testicle, hypogonadism and infertility. Of the 112 men referred to our facility for treatment of chronic orchialgia 30% did not respond to the cord block and were not offered MDSC.

Postoperative examination and verbal pain scales were compared with preoperative findings. Responses to MDSC were either complete, partial or none. Complete responders rated pain 0 on a 10-point scale at latest followup. Partial responders rated their pain at least 50% less than before surgery. Nonresponder pain was reported as unchanged.

Procedure

MDSC was first described in 1978 by Devine and Schellhammer in a report on 2 men undergoing the procedure for chronic orchialgia.⁶ With our approach all patients receive general anesthesia. A low inguinal incision is made to expose the external inguinal ring. The ilioinguinal nerve is identified typically emerging laterally from the external inguinal ring, and a 2 to 3 cm segment is excised and ligated (fig. 1). The proximal end is then buried under the external inguinal ring to decrease the risk of neuroma formation. The spermatic cord is then elevated and brought to rest on a 5/8-inch Penrose drain.

An operating microscope set at 8 times magnification is brought to the field. The anterior spermatic cord fascia is opened for 3 to 4 cm to expose the cord contents (fig. 2). Micro-Doppler ultrasound is used to identify the location of arterial flow. The testicular, cremasteric, and deferential arteries and branches are identified and secured with microvessel loops. The internal spermatic veins are ligated and divided. Electrocautery is used to divide all of the cremasteric musculature and spermatic cord fascia. Several lym-

TABLE 2. *Demographics*

No. men	79
Mean age (range)	40.3 (17-68)
No. testicular units	95
No. bilat	16
No. unilat	63
Mean mos followup (range)	20.3 (1-102)
Mean mos preop pain	62 (5-252)
No. etiology of orchialgia (%):	
Unknown	34 (43)
Vasectomy	13 (16)
Herniorrhaphy	7 (9)
Infection	7 (9)
Trauma	6 (7)
Physical straining*	5 (6)
Varicolectomy	2 (3)
Back injury	2 (3)
Back surgery	2 (3)
Previous radiation therapy	1 (1)

* Vigorous sex, exercise, lifting.

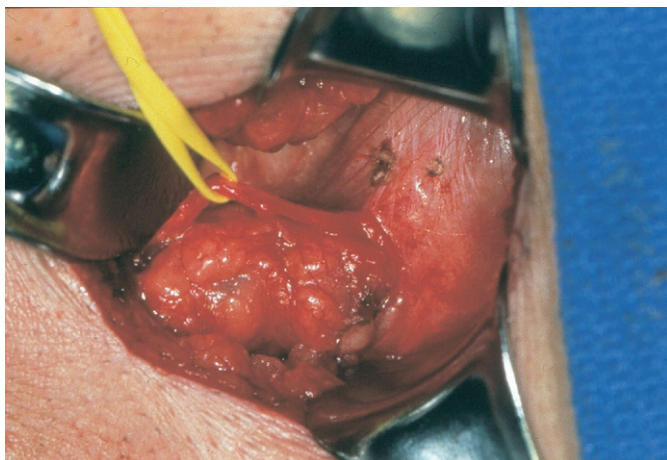


FIG. 1. Isolation of ilioinguinal nerve

phatics are also spared as this is believed to prevent hydrocele formation (fig. 3).

In men who have not undergone vasectomy the vas deferens is preserved to prevent epididymal congestion, which is thought to contribute to post-vasectomy pain syndrome. In this circumstance the vas is stripped of the fascial covered outer layer to ablate afferent nerve pathways carrying potentially noxious stimuli. In those who underwent prior vasectomy the vas is divided again to ensure that any neural fibers within and on the vas are destroyed. The cord is placed back into its original position and 10 cc 0.5% bupivacaine without epinephrine is injected into the wound, which is closed in layers. Before closure pulsatile flow within the preserved arteries is checked with the micro-Doppler. If poor flow due to spasm is noted then topical papaverine is applied to the vessel surface to encourage vasodilation.

RESULTS

Complete pain relief was noted in 67 (71%) testicular units, partial relief in 17 (17%) and pain was unchanged in 11 (12%). On average pain reduction in partial responders was 57% less ($p = <0.001$, CI 3.579–6.135, SD 2.21) where the

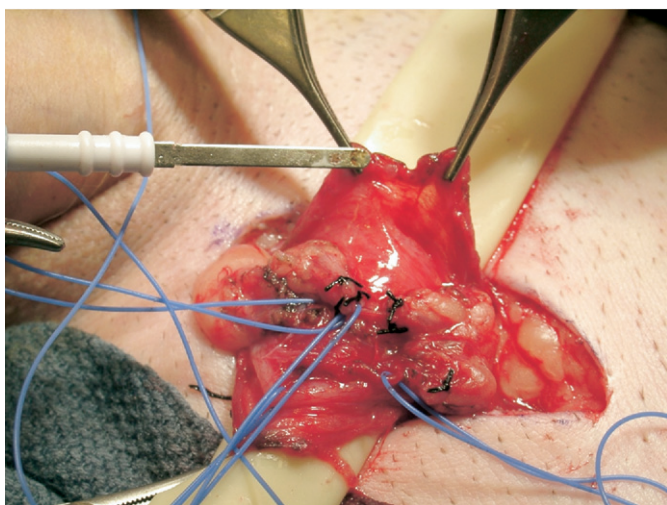


FIG. 2. Dissection of spermatic cord. Preparing to divide spermatic cord fascia.

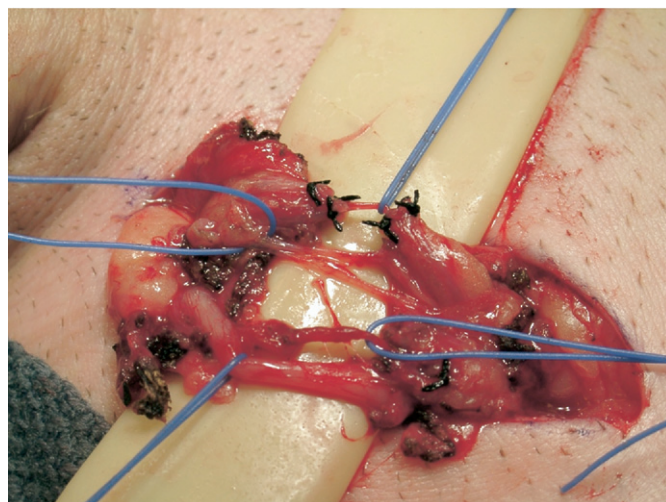


FIG. 3. Completed dissection of cremasteric artery, lymphatics, internal spermatic artery, vas deferens (top to bottom).

mean preoperative pain was 7 and the mean postoperative pain was 3 on the 10-point scale. No patients reported worse pain. Etiology was unknown in 34 (43%) patients, vasectomy in 13 (16%), herniorrhaphy in 7 (9%), infection in 7 (9%), trauma in 6 (7%), physical straining in 5 (6%), varicocelectomy in 2 (3%), back injury in 2 (3%), back surgery in 2 (3%) and previous radiation therapy in 1 (1%) (table 2).

Complications included testicular atrophy in 2 (3%) patients, superficial wound infection in 2 (3%) which responded to oral antibiotics and local wound care, hydrocele in 2 (3%) which resolved in 6 months in 1 (the other patient did not require further treatment), a seroma that drained spontaneously in 1 (1%) and an incisional hematoma in 1 (1%). There were no complaints of hypoesthesia or hyperesthesia of the scrotum, penile shaft, inguinal or medial thigh skin. There were also no clinical complaints from the 2 men who had testicular atrophy and they were free of orchialgia. Interestingly both men had a history of inguinal surgery.

DISCUSSION

Chronic orchialgia impacts quality of life profoundly such that after failure of medical management men are often willing to undergo orchiectomy for relief, risking hypogonadism and psychological distress. Urologists are left with a variety of surgical options with limited published information to guide their treatment recommendations (table 1). In addition, specific guidelines as to what procedure is indicated for a particular presentation are lacking. Patients may present with diffuse pain involving the testicle, epididymis and cord structures or possibly just the epididymis for example. No procedure has been reported to be routinely successful for any type of orchialgia. Our goal was to evaluate our single center experience with MDSC in men with diffuse testicular pain with or without epididymal pain.

Chronic pain follows chronic respiratory disorders as the most common reason to visit a doctor. Progress in the understanding of the mechanisms of chronic pain and its treatment are slowly evolving. It is now recognized that chronic orchialgia is another condition in the spectrum of chronic pain syndromes, such as interstitial cystitis, that are difficult to manage.⁷ Once thought of as static the PNS and CNS

are involved in the wind-up phenomenon of chronic pain. Plasticity of the nervous system has a central role where repeated noxious stimulation of the nociceptors in the periphery results in permanent changes in the PNS and CNS.²

Nociceptors and their neurons display a phenomenon known as sensitization following repeated stimulation. In the PNS the neurons undergo modulation which results in a decreased threshold for depolarization, increased frequency of response and a decreased response latency time. After a while they can begin to fire spontaneously.⁷

In the CNS similar processes as in the periphery occur leading to phenotypic changes including up-regulating intracellular cascade components and N-methyl-D-aspartate receptors. Even neurons adjacent to those involved in responding to the painful stimulus begin to fire on their own.⁷

The logic behind MDSC is that by removing the afferent nerve stimulus, the changes in the PNS and CNS can be down-regulated and the chronic pain stops. It is postulated that the 12% (11) of testicular units in our series that did not respond to surgery did so due to permanently up-regulated processes in the CNS despite having a satisfactory temporary response to the spermatic cord block. A recent series of 11 men treated with modified MDSC reported an increased rate of local hypersensitivity which may be due to preservation of the ilioinguinal nerve in this series.⁸ This nerve is routinely divided in our series and there have been no reports of local hypersensitivity. Pudendal nerve entrapment may also be responsible for persistent pain after MDSC but typically these cases do not respond to the anterior spermatic cord block. More complex and centrally located pathologies may also be responsible for the pain, such as musculoskeletal injury, particularly of the lumbosacral region. For this reason preoperative lower spinal cord MRI is performed on our patients if the history and physical examination suggest lower back pain or disc disease.

With this logic orchietomy, especially by the inguinal approach, would theoretically be efficacious in ablating the afferent nerve stimulus. However, numerous studies show variable success rates. Davis et al reported a success rate of 74% in a small series of 15 (table 1).¹ Another small series by Yamamoto et al shows 3 of 4 patients having complete success during an unspecified followup period.⁹ Given that there are limited studies demonstrating success with orchietomy and risks of physiological and psychological damage, we believe that this procedure should be the last resort for chronic orchialgia, especially when there is a less surgically ablative alternative such as MDSC which preserves the testicle and has similar or better rates of success.

Epididymectomy has also been performed for chronic orchialgia with variable success. In our practice it is reserved for patients whose pain localizes strictly to the epididymis on history and physical examination. Most commonly this occurs following vasectomy in which obstructive epididymitis develops. Complete success rates for epididymectomy are low (table 1). All studies listed in this report except 1 do not mention followup duration. Vasectomy reversal for presumed post-vasectomy pain syndrome also has variable success rates and defeats the original intention of the patient to be sterile.¹⁰⁻¹² In the current study 13 testicular units were available for analysis where vasectomy was the etiology of orchialgia. These numbers are few but given the success of MDSC for chronic orchialgia, vasectomy reversal would be

more appropriately offered to those men desiring renewed fertility and alleviation of orchialgia.

Other less studied surgical treatments for chronic orchialgia in the literature include laparoscopic denervation of the spermatic cord, which may fail to identify all neural conduits of pain coming from the testicle. In addition, dividing these nerves within the abdomen or pelvis may result in sensory loss to areas outside of the testicle and scrotal contents.

In this series medical therapy had failed in our patients including trials of antibiotics, nonsteroidal anti-inflammatory drugs and/or narcotic analgesics before referral to our clinic. Most patients experienced treatment failure including antidepressants and anticonvulsants before surgery. Also many had sought relief with alternative medical therapy including regional nerve blocks, physical therapy, myofascial release, biofeedback, psychotherapy or acupuncture. A recent report in the literature suggested that medical management of idiopathic chronic orchialgia (specifically not related to vasectomy) can be successful with antidepressants or anticonvulsants.¹³ However, the series has a short 3-month followup, few participants and fails to mention the side effects of these medications as well as whether these men could ultimately stop treatment without recurrence of pain.

Weaknesses of this report include a retrospective design and the absence of a validated questionnaire. We are unaware of such an instrument for this indication. Other faults include selection bias as patients were referred either by other physicians or self-referred. In addition, the lack of an objective end point in assessing pain continues to plague studies assessing success of various treatments. The use of a verbal pain rating scale in this study has been criticized. However, studies have demonstrated that the simple verbal rating scale correlates well with the visual analog scale for pain, particularly when the primary language for the subject was the same as the questionnaire.¹⁴ We now use a visual analog scale for assessment of preoperative pain for new patients and of postoperative pain in all patients at followup.

Clearly there is not a defined surgical algorithm for defining which modality for treating orchialgia is best suited for a respective etiology. MDSC appears to work well for all etiologies but is not successful in every case. Chronic pain remains a dilemma and as further research provides insight into the mechanisms, new treatments will presumably emerge. In the meantime MDSC appears to be a reasonable approach to rid the pain and spare the testicle. Other benefits may include stopping chronic drug use, and resumption of daily living activities as well as work, sex and exercise, which are frequently either compromised or eliminated due to the pain.

CONCLUSIONS

MDSC is a minimally invasive, effective and durable management option for chronic orchialgia refractory to medical management. The success rate is acceptable allowing patients to get off chronic medications, complications are rare, and the testicle is preserved benefiting the patient physiologically and psychologically.

Abbreviations and Acronyms

CNS	=	central nervous system
MDSC	=	microsurgical denervation of the spermatic cord
MRI	=	magnetic resonance imaging
PNS	=	peripheral nervous system

REFERENCES

- Davis BE, Noble MJ, Weigel JW, Foret JD and Mebust WK: Analysis and management of chronic testicular pain. *J Urol* 1990; **143**: 936.
- Woolf CJ and Salter MW: Neuronal plasticity: increasing the gain in pain. *Science* 2000; **288**: 1765.
- Zoltan E, Lerlise V and Hanno PM: Painful bladder syndrome/interstitial cystitis. *AUA Update* 2006; **25**: lesson 9.
- Levine LA, Matkov TG and Lubenow TR: Microsurgical denervation of the spermatic cord: a surgical alternative in the treatment of chronic orchialgia. *J Urol* 1996; **155**: 1005.
- Levine LA and Matkov TG: Microsurgical denervation of the spermatic cord as primary surgical treatment of chronic orchialgia. *J Urol* 2001; **165**: 1927.
- Devine CJ and Schellhammer PF: The use of microsurgical denervation of the spermatic cord for orchialgia. *Trans Am Assoc Genitourin Surg* 1978; **70**: 149.
- Bolay H and Moskowitz MA: Mechanisms of pain in chronic syndromes. *Neurology* 2002; **59**: S2.
- Hamoui O, Miranda-Sousa AJ, Webster JC and Carrion RE: Modified microscopic denervation of the testes for chronic orchialgia. *J Sex Med* 2008; **5**: 38, abstract 100.
- Yamamoto M, Katsuno S and Miyake K: Management of chronic orchialgia of unknown etiology. *Int J Urol* 1995; **2**: 47.
- Shapiro EI and Silber SJ: Open-ended vasectomy, sperm granuloma, and postvasectomy orchialgia. *Fertil Steril* 1979; **32**: 546.
- Myers SA, Mershon CE and Fuchs EF: Vasectomy reversal for treatment of the post-vasectomy pain syndrome. *J Urol* 1997; **157**: 518.
- Nangia AK, Myles JL and Thomas AJ Jr: Vasectomy reversal for post-vasectomy pain syndrome – a clinical and histological evaluation. *J Urol, suppl.*, 2000; **163**: 345, abstract 1530.
- Sinclair AM, Miller B and Lee LK: Chronic orchialgia: consider gabapentin or nortriptyline before considering surgery. *Int J Urol* 2007; **14**: 622.
- Cork RC, Isaac I, Elsharydah A, Saleemi S, Zavisca F and Alexander L: Comparison of the verbal rating scale and the visual analog scale for pain assessment. *Int J Anesthesiol* 2004; **8**: 1.
- Choa RG and Swami KS: Testicular denervation. A new surgical procedure for intractable testicular pain. *Br J Urol* 1992; **70**: 417.
- Ahmed I, Rasheed S, White C and Shaikh NA: The incidence of post-vasectomy testicular pain and the role of nerve stripping (denervation) of the spermatic cord in its management. *Br J Urol* 1997; **79**: 269.
- Heidenreich A, Olbert P and Engelmann UH: Management of chronic testalgia by microsurgical testicular denervation. *Eur Urol* 2002; **41**: 392.
- Cadeddu JA, Bishoff JT, Chan DY, Moore RG, Kavoussi LR and Jarrett TW: Laparoscopic testicular denervation for chronic denervation. *J Urol* 1999; **162**: 733.
- West AF, Leung HY and Powel PH: Epididymectomy is an effective treatment for scrotal pain after vasectomy. *BJU Int* 2000; **85**: 1097.
- Ducic I and Dellon AL: Testicular pain after inguinal hernia repair: an approach to resection of the genital branch of the genitofemoral nerve. *J Am Coll Surg* 2004; **198**: 181.